

V. SIHOTSKÝ^{1,2}, P. BEREK^{1,2}, I. KOPOLOVETS^{1,4},
M. KUBÍKOVÁ^{1,2}, M. TOMEČKO¹, M. STANČÁKOVÁ^{2,3},
I. DRAHOVSKÁ^{2,3}, M. FRANKOVIČOVÁ^{1,2}



AORTOBIFEMORAL GRAFT INFECTION: POSSIBILITIES OF TREATMENT

Clinic of Vascular Surgery VÚSCH a.s.¹,
Faculty of Medicine PJ Šafárik²,
University Hospital of L. Pasteur³, Košice,
Slovakia

DSME "Uzhhorod National University"⁴, Uzhhorod,
Ukraine

В статье описываются два клинических случая оказания помощи пациентам с инфицированными аортобифеморальными протезами. В обоих случаях протез был удален. В первом случае было принято решение сделать экстраанатомическую реваскуляризацию нижних конечностей после полного удаления протеза из-за вирулентной инфекции (*Staphylococcus aureus* и Гр+ бактерии) и протезо-энтеральной фистулы. Было выполнено аксило-бифеморальное шунтирование. Во втором случае, когда инфекция была не столь вирулентной (*Staphylococcus epidermidis*), было принято решение провести эндартерэктомию аорты и подвздошных артерий, а также для реконструкции использовали бедренную вену. Оперативные вмешательства прошли успешно. У обоих пациентов в настоящее время нет признаков инфекции и перемежающейся хромоты. Инфекция протеза является одним из наиболее серьезных осложнений аортобифеморального шунтирования, поэтому профилактика инфекции очень важна. Важно соблюдать все правила асептики и антисептики во время операции. Лечение инфекции протеза основано на внутривенном введении антибиотиков и удалении инфицированного синтетического материала. Реваскуляризация конечностей после удаления протеза может быть обеспечена путем экстраанатомического шунтирования или артериальной реконструкции «in situ».

Ключевые слова: инфекция, аортобифеморальный протез, реваскуляризация, экстраанатомическое шунтирование

Authors describe two case reports of patients with infected aortobifemoral graft. Both were treated by total graft excision. In the first case they decided for extra anatomical revascularization of lower extremities after total graft excision, because of virulent infection (*Staphylococcus aureus* and G+ bacteria) and graft enteral fistula. They performed axilobifemoral bypass grafting. In the second case, where infection was not so virulent (*Staphylococcus epidermidis*) they decided for in situ reconstruction with desobliterated native aorta, iliac arteries and femoral vein. Both patients are now without signs of infection and they can walk without claudication pain. Graft infection is one of the most serious complications of aortobifemoral bypass surgery therefore the prevention of infection is very important. It is important to keep all rules of asepsis and antisepsis during surgery. Treatment of graft infection is based on intravenously administered antibiotics and excision of infected graft. Limb revascularization after graft removal can be provided by extra anatomical bypass or in situ arterial reconstruction.

Key words: infection, aortobifemoralgraft, revascularization, extra anatomical bypass

Novosti Khirurgii. 2017 Nov-Dec; Vol 25 (6): 655-661

Aortobifemoral Graft Infection: Possibilities of Treatment

**V. Sihotský, P. Berek, I. Kopolovets, M. Kubíková, M. Tomečko,
M. Stančáková, I. Drahovská, M. Frankovičová**

Introduction

Prothetic graft infection is a feared complication of aortic surgery. The reported incidence of infection of vascular prosthesis varies. Infection occurs after 0.2% to 5% of operations and is influenced by the implant site, indication for the surgery, concomitant disease, and host immune system [1]. Limb loss occurs in 25% of cases of infection and mortality reaches 40% [2]. The incidence of aortic graft

infection decreases in last years due to more precise asepsis and antisepsis in perioperative period. Antibiotics also reduced the risk of infection. Early diagnosis and treatment of the graft infections are crucial to avoid major complications like sepsis, bleeding and to avoid death. Diagnosis is based on CT, MRI eventually on PET-CT [1]. Surgical treatment includes excision of the infected graft and revascularisation by extra anatomical or in situ bypass [1, 3].

Case report 1

Sixty-four years old lady came in September 2009 because of gluteal and femoral claudications after 50 m of walking. Except this she suffered from chronic ischemic heart disease, hypertension and diabetes mellitus of the II type. She was smoker. Angiography revealed peripheral arterial occlusive disease, aortoiliac type, TASC D, which was not appropriate to endovascular treatment. We performed aortobifemoral bypass grafting with silver-coated Dacron graft in September 2009. Postoperative course was without serious complications and patient was discharged home on the twelfth postoperative day. In June 2012 she came because of thrombosis of right limb of aortobifemoral graft. We performed thrombectomy of the right limb of the graft and postoperatively PTA of the stenosis of the right distal anastomosis. In April 2013 she came again because of acute limb ischemia of the right lower extremity, we performed thrombectomy of the right limb of the graft again and because of the persistent stenosis of the distal anastomosis, we performed resection of the distal anastomosis with extension of the graft distally at the nearest patent portion of deep femoral artery. In June 2014 patient started to suffer from fever. CRP was elevated. We performed CT angiography which revealed false aneurysm in right groin (Fig. 1.).

Because of suspicion at infection we resected the false aneurysm in the right groin and revascularized right lower extremity by in-situ saphenous graft. Despite of massive antibiotic treatment on the tenth postoperative day massive bleeding occurred in the right inguinal area. We operated the patient immediately and we found massive infection in the right groin. We decided for excision of infected graft and we restored blood supply to right lower extrem-

Fig. 1. CT-angio, false aneurysm of right distal anastomosis – yellow arrow.

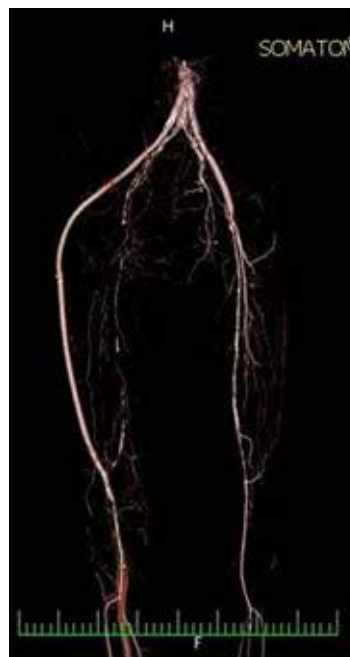
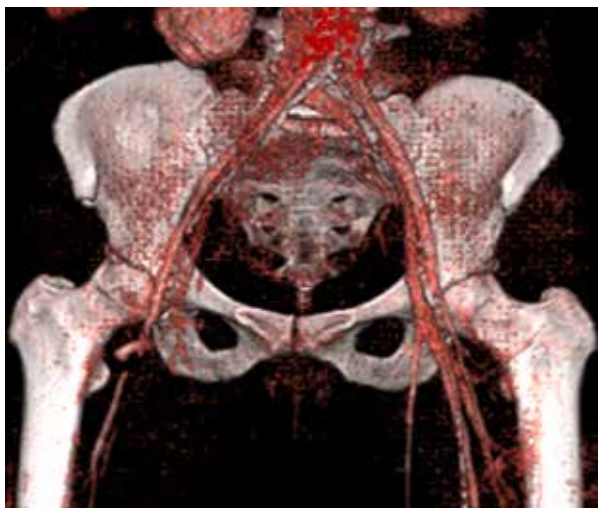
Fig. 2. CT-angio, Extra ananatomical iliaco (prosthesis) popliteal lateral bypass, anastomoses are marked by yellow arrows.

ity by extra anatomical iliaco-popliteal lateral bypass grafting. Proximal anastomosis was constructed in retroperitoneum in macroscopically infection free part of the right limb of aortobifemoral graft. The graft of extra anatomical bypass was placed on the lateral site of the thigh and approach to popliteal artery was from lateral incision. CT –angio reconstruction shows this lateral popliteal extra anatomical bypass (Fig. 2.).

After excision of the infected graft the right groin was left open for secondary healing. Culture revealed *Staphylococcus epidermidis* MRSE, *Staphylococcus haemolyticus* MRSH, *Proteus mirabilis* a *Pseudomonas aeruginosa*. We administered massive antibiotic treatment according culture. Extra-anatomical bypass was patent and the right lower extremity was viable. The right groin healed secondary (Fig 3.).

Patient was discharged after ten weeks of hospitalization without signs of infection. The patient was followed up then, she was without signs of infection, the extra anatomical bypass was patent. She started to be septic in February 2015. PET–CT revealed increased metabolic activity in the body of the prosthesis (Fig 4).

Septic fever, increased CRP and the focus in the body of the prosthesis at PET-CT confirmed graft infection of the remnant of the Dacron graft. We decided for total graft excision of the whole infected graft in March 2015. First we revascularized limbs by axilobifemoral bypass from left axillar artery to left common femoral artery. Then we constructed cross over femoro femoral bypass

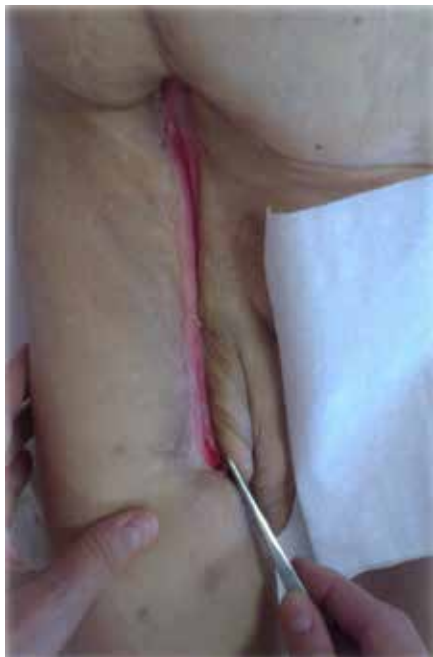

Fig. 3. Right groin: secondary healed.

from left groin to the previously constructed right iliacopopliteal lateral bypass which was without signs of infection. Then we performed re-laparotomy. We found covered perforation of duodenum (part D3) that was in direct contact with the Dacron graft. The perforation was the direct cause of the infection. We removed the infected Dacron graft and the defect in duodenum was over sewn. We added nutrition jejunostomy. There was prolonged bowel paralysis in postoperative course. The patient was fed by parenteral and enteral nutrition and parenteral for two weeks. After two weeks a peroral intake of food was able. Cultures from the graft and also surrounding tissue were negative but despite the negative cultures we administered patient antibiotics according previous cultures. We administered vankomycin, meropenem, colimycin and fluconazol intravenously.

The patient was discharged at 34th postoperative day. The arterial reconstructions were patent. Today she is two years after explantation of the infected graft without signs of infection, CRP level is normal, arterial reconstructions are patent, she is able to walk without claudication by slow walk.

Case report 2

Fifty-sevenyears old lady came in June 2010 because of gluteal and femoral claudications after 20-30 meters of walking. She had been after CABG in year 2004 and she was smoker. Except this she had no other serious underlying diseases. Angiography revealed aortoiliac atherosclerosis, TASC D and in July 2010 we also performed

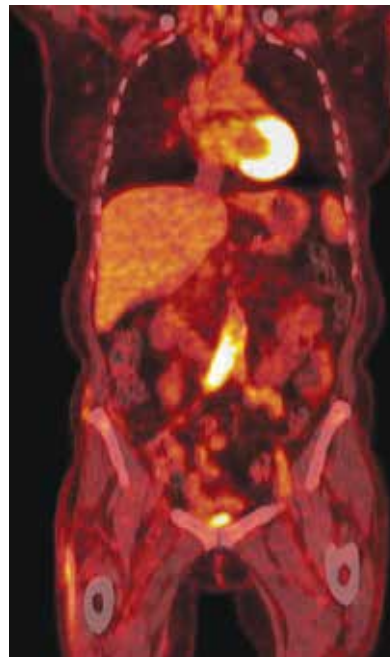


Fig. 4. PET-CT infected prosthesis of aortobifemoral graft. Focus of infection is marked by yellow arrow.

aortobifemoral bypass grafting with silver-coated Dacron graft. Postoperative course was without complications and the patient was discharged on the 8th postoperative day. Then she was followed up, she was without any symptoms and she was able to walk without ischemic pain. In January 2012 she came because of seroma in left groin, we performed puncture of the seroma and swab cultures were negative. In February 2014 she came because of fistula in right groin, we performed revision of the right inguinal area and we found an abscess. We performed lavage and drainage of the abscess and took culture that revealed *Staphylococcus epidermidis*. We administered intravenous antibiotic treatment (gentamycin, ciprofloxacin and clindamycin) according to culture. CRP was not elevated. In May 2014 she came again because of perigraft fluid in the right groin at CT. We performed revision of the right groin, again took cultures, performed lavage and drainage. Cultures were negative, but despite of this we administered gentamycin and vancomycin intravenously. In October 2016 the patient came again because of pain and fistula in left groin. CRP was elevated to 101 mg/l. CT confirmed perigraft fluid around whole aortobifemoral graft and false aneurysm in the left groin (Fig. 5., Fig. 6.).

We decided for total excision of the infected graft. We performed re-laparotomy, we found that the whole graft was surrounded by fluid. We did not find any communication with gastrointestinal tract. Because there was no communication with gastrointestinal tract and the previous culture revealed *Staphylococcus epidermidis*, that is less virulent,

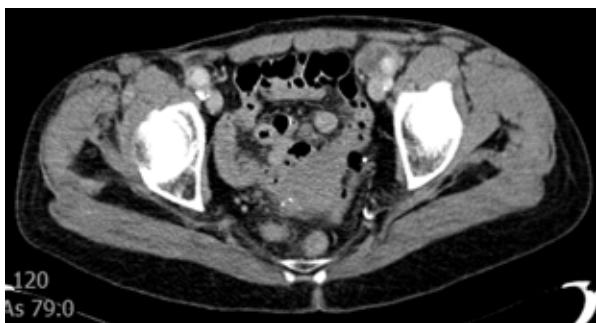

Fig. 5. CT – Perigraft fluid, yellow arrow.

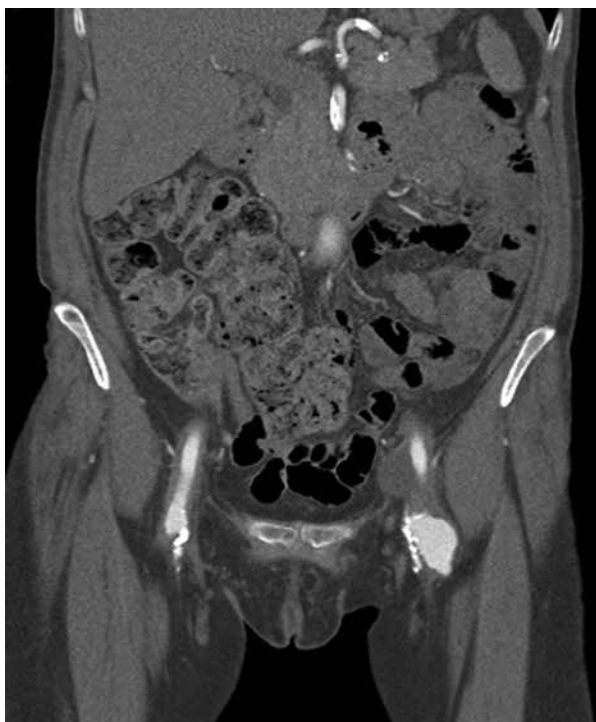

Fig. 6. Perigraft fluid – yellow arrow, false aneurysm – blue arrow.

we decided for in situ reconstruction. Aorta and both common iliac arteries were desobliterated by local endarterectomy. Left external iliac artery was revascularised by Vollmar endarterectomy from left groin. It was not able to perform Vollmar endarterectomy of external iliac artery at the right side therefore we reconstructed right iliac external artery by right femoral vein. We used in situ reconstruction with only autologous material. Postoperative course was without complications. Cultures from perigraft fluid and the graft were negative. But we administered antibiotics (ciprofloxacin and clindamycin) intravenously. She was discharged at the 9th postoperative day at per oral antibiotic treatment (ciprofloxacin). She is followed up in our out-patient ambulance. Now she is without sign of infection, wounds are healed, CRP is 15 mg/l. She walks without claudication pain; right lower extremity is without edema.

Discussion

Aortobifemoral bypass grafting is considered to be the gold standard of treatment of aortoiliac atherosclerosis. Long term results of aortobifemoral graft are excellent. Its five-year patency is about 90%. Late complications are mainly thrombosis of the graft, graft infection and also false aneurysm of proximal or distal anastomosis. The most serious complication is graft infection.

The reported incidence of infection involving a vascular prosthesis varies, infection occurs after 0.2% to 5% of operations [1]. Aortic graft infections can develop months to years after implantation, and thus the long-term incidence is higher [1, 3]. Local risk factor of graft infection is presence of postoperative hematoma or seroma. Also repeated trombectomies can increase the risk of infections. Underlying diseases like diabetes mellitus, malnutrition, corticosteroid drugs therapy or chronic renal failure can be also systemic risk factor of graft infection [4]. Graft infections are caused mainly by *Staphylococcus aureus*, but recently also by *Staphylococcus epidermidis* or G-negative bacteria. G-negative bacteria are typical for aortoenteric fistulas [5]. Infections caused by *Staphylococcus aureus* or G-negative bacteria are highly virulent. Graft infections can lead to bleeding from anastomosis or graft occlusion. The source of infection was duodenum in our case. The reason of duodenal perforation might be technical failure by the first operation. There was probably the direct contact of the prosthesis with duodenum and this could lead to perforation of duodenum with contamination of the graft by duodenal content. It is important to avoid contact between graft and duodenum. Retroperitoneal tissue should be inserted between graft and duodenum. If this is not possible, flap from omentum should be constructed and inserted between duodenum and graft.

Infections caused by *Staphylococcus epidermidis* are less virulent [6]. They can develop months or years after the operative period. Typical symptom is false aneurysm or periprotetic fluid. Systemic signs of infection are not so common. Diagnosis is based on clinical symptoms. There can be elevation inflammatory markers, CRP or procalcitonine in serum. Positivity of hemoculture is not common and is referred about 5% [1]. Sonography can reveal hematoma, seroma or abscess in subcutaneous tissue or around graft. Any presence of perigraft fluid or gas bubbles at CT beyond three months after operation indicates graft infection. Diagnostic criteria at CT consistent with infection include the loss of normal tissue planes of the retroperitoneal or subcutaneous perigraft structures collections of fluid or gas around

the graft, false aneurysm formation, hydronephrosis, and adjacent vertebral or bony osteomyelitis. MRI provides anatomic imaging equivalent to that of CT but is better able to distinguish between perigraft fluid and fibrosis on the basis of differences in signal intensity between T1- and T2-weighted images. All radionuclide imaging techniques aim to demonstrate abnormal accumulation of leukocytes in perigraft tissue for the diagnosis of graft infection but do not provide anatomic detail. However, they can be correlated with MRI and CT to delineate the anatomic extent of infection. The accuracy of indium 111-labeled WBC scans approaches 80% to 90% in detecting graft infection [1]. Nowadays PET or with combination with CT like PET- CT seems to be the most accurate imaging method in detection of graft infection. In case of graft enteral fistula or graft enteral erosion endoscopy of upper abdomen can be helpful.

The goals of managing vascular graft infections involve initial and long-term eradication of the local and systemic septic process and maintenance of normal arterial perfusion to involved end-organ and limb tissues. In case of graft infection, the infected part should be excised. The most common site of infection of aortobifemoral graft is its inguinal portion. When proximal part of limb is incorporated into healthy retroperitoneal tissue, excision only of the inguinal part of the prosthesis can be satisfactory [7]. But when there are signs of infection of the whole graft, the prosthesis should be excised completely. In case of aortobifemoral graft blood supply to extremities should be restored. There are two possibilities of revascularization of limbs, extra-anatomical axilo-bifemoral bypass or in-situ bypass. Extra-anatomical bypass is classical approach in the treatment of the graft infection in this localization that includes total graft excision, blind closure of aortic stump, debridement of grossly infected tissue bed and restoring of blood supply by axilobifemoral bypass. In case when only limb of graft is infected, without infection of the whole graft, excision of the infected part may be sufficient. The revascularization of the extremity is restored by extra-anatomical obturator bypass from healthy part of the graft through foramen obturatum medially to popliteal artery. Limb loss is by extra-anatomical bypass referred 10% to 25%, perioperative mortality is 15 to 22%, one-year survival after operation is 60% to 80% and infection in axilobifemoral bypass can be seen in 3% to 25% [2].

Relatively high mortality and morbidity of extra-anatomical bypasses led to involving of in-situ reconstructions into the treatment of graft infections. Advantage of in situ reconstructions is that they are anatomical and with autologous material but they are appropriate only for less

virulent infections. Autologous grafts, cryopreserved arterial allograft or antibiotic treated prosthesis can be used for in-situ reconstruction. Autologous graft can be vein or desobliterated arterial graft. Great saphenous vein can be used to replace peripheral grafts but is not large enough for insitu aortoiliac reconstruction. Promising results can be seen by using of femoral veins that can replace aorta of diameter up to 26 mm. Clagett refers perioperative mortality 10%, primary patency 80% after six years and early limb loss only 6% using femoral vein. Five-year survival was 52% [8]. Only 15% of patients had signs of chronic venous insufficiency after removal of femoral vein. Occluded aorta and common iliac artery can be desobliterated by direct endarterectomy. External iliac artery can be desobliterated by endarterectomy by Vollmar loop. Such desobliterated external, common iliac artery and aorta can serve as autologous arterial in situ graft.

A second option for insitu replacement is the use of aortic and iliofemoral arterial segments harvested from transplant donors and rendered nonantigenic by cryopreservation. The results are comparable with results of reconstructions with femoral vein. But aneurysmatic dilatation, stenosis and degeneration of allograft can be seen more frequently compared with femoral vein in situ reconstruction [9, 10].

Use of antibiotic coated prosthetic conduit for in situ replacement of infected grafts is a treatment option in selected circumstances. Rifampycin is often used for this purpose. When antibiotic coated prosthesis is considered to be used for insitu reconstruction, the infection should be less virulent without systemic signs [7, 11]. Such graft should be covered by muscle flap in inguinal area or omental flap in peritoneal cavity. Six-week antibiotic therapy should be added after placement of antibiotic coated prosthesis. Reinfection rate is referred 5-10% [11]. Extra-anatomical reconstruction and also in situ reconstruction should be followed by 2-6 weeks of intravenous antibiotic treatment.

We prefer in situ reconstruction with autologous material when it is possible, what we did in the second case. In the first case we were afraid of virulent infection, because the first in situ reconstruction in this patient which was constructed with saphenous graft in right inguinal area led to massive bleeding. We were afraid that the *Staphylococcus aureus* infection could lead also to infection of insitu reconstruction in aortoiliac position with massive bleeding from aorta. Therefore, we decided for extra-anatomical reconstruction, axilobifemoral bypass grafting.

Prevention of graft infection is imperative, and the surgical team must be cognizant of preoperative,

operative, and postoperative prophylactic measures. To prevent infection of vascular prosthesis it is important to protect vascular grafts from contact with any potentially contaminating source, especially the exposed skin adjacent to the operative field, with the use of iodine impregnated plastic drapes. Concomitant gastrointestinal procedures during cavitory grafting procedures should be avoided to prevent contamination of the graft with enteric organisms [1]. It is important to avoid direct contact of the graft with duodenum to prevent graft enteral fistula.

Conclusions

Graft infection in aortoiliac position is one of the most serious complications of bypass surgery and is associated with high mortality and morbidity. Diagnosis is based on clinical symptoms, elevation of inflammatory markers like CRP and procalcitonin. Imaging methods like CT, MRI or PET-CT can help to confirm the diagnosis. The treatment is intravenous administration of antibiotics and excision of the infected graft. After removal of the infected graft, blood supply to extremities should be restored. One of the possibilities is extra-anatomical bypass and the second is in situ reconstruction. The best outcomes are with autologous graft like femoral vein or desobliterated arteries. Graft infection is one of the most serious complications of aortobifemoral bypass surgery therefore the prevention of infection is very important. It is important to keep all rules of asepsis and antisepsis during surgery.

Affirmation

I declare that both patients are informed about the publication of their case reports and they agree with publication.

Conflict of interest

None.

Funding

None.

LITERATURE

1. Back Martin R. Chapter 42: Local Complications: Graft Infection. In: Cronenwett JL, Johnston KW. Rutherford's Vascular Surgery. 8-th ed. Philadelphia, PA: Saunders/Elsevier; 2014. p. 654-72.e2.
2. O'Hara PJ, Hertzner NR, Beven EG, Krajewski LP. Surgical management of infected abdominal aortic grafts: review of a 25-year experience. *J Vasc Surg.* 1986 May;3(5):725-31.
3. Campbell WB, Tambour LJ, Geens VR. Local complications after arterial bypass grafting. *Ann R Coll Surg Engl.* 1994 Mar;76(2):127-31.

4. Campbell WB, Tambour LJ, Geens VR. Local complications after arterial bypass grafting. *Ann R Coll Surg Engl.* 1994 Mar;76(2):127-31.
5. Maltezou HC, Giamarellou H. Community-acquired methicillin-resistant *Staphylococcus aureus* infections. *Int J Antimicrob Agents.* 2006 Feb;27(2):87-96.
6. Bergamini TM, Bandyk DF, Govostis D, Vetsch R, Towne JB. Identification of *Staphylococcus epidermidis* vascular graft infections: a comparison of culture techniques. *J Vasc Surg.* 1989 May;9(5):665-70.
7. Bandyk DF, Novotney ML, Back MR, Johnson BL, Schmacht DC. Expanded application of in situ replacement for prosthetic graft infection. *J Vasc Surg.* 2001 Sep;34(3):411-19; discussion 419-20.
8. Clagett GP, Bowers BL, Lopez-Viego MA, Rossi MB, Valentine RJ, Myers SI, et al. Creation of a neo-aortoiliac system from lower extremity deep and superficial veins. *Ann Surg.* 1993 Sep;218(3):239-48; discussion 248-49.
9. Kieffer E, Gomes D, Chiche L, Fléron MH, Koskas F, Bahnini A. Allograft replacement for infrarenal aortic graft infection: early and late results in 179 patients. *J Vasc Surg.* 2004 May;39(5):1009-17.
10. Bisdas T, Bredt M, Pichlmaier M, Aper T, Wilhelm M, Bisdas S, et al. Eight-year experience with cryopreserved arterial homografts for the in situ reconstruction of abdominal aortic infections. *J Vasc Surg.* 2010 Aug;52(2):323-30. doi: 10.1016/j.jvs.2010.02.277.
11. Oderich GS, Bower TC, Hofer J, Kalra M, Duncan AA, Wilson JW, et al. In situ rifampin-soaked grafts with omental coverage and antibiotic suppression are durable with low reinfection rates in patients with aortic graft enteric erosion or fistula. *J Vasc Surg.* 2011 Jan;53(1):99-106, 107.e1-7; discussion 106-7. doi: 10.1016/j.jvs.2010.08.018.

REFERENCES

1. Back Martin R. Chapter 42: Local Complications: Graft Infection. In: Cronenwett JL, Johnston KW. Rutherford's Vascular Surgery. 8-th ed. Philadelphia, PA: Saunders/Elsevier; 2014. p. 654-72.e2.
2. O'Hara PJ, Hertzner NR, Beven EG, Krajewski LP. Surgical management of infected abdominal aortic grafts: review of a 25-year experience. *J Vasc Surg.* 1986 May;3(5):725-31.
3. Campbell WB, Tambour LJ, Geens VR. Local complications after arterial bypass grafting. *Ann R Coll Surg Engl.* 1994 Mar;76(2):127-31.
4. Campbell WB, Tambour LJ, Geens VR. Local complications after arterial bypass grafting. *Ann R Coll Surg Engl.* 1994 Mar;76(2):127-31.
5. Maltezou HC, Giamarellou H. Community-acquired methicillin-resistant *Staphylococcus aureus* infections. *Int J Antimicrob Agents.* 2006 Feb;27(2):87-96.
6. Bergamini TM, Bandyk DF, Govostis D, Vetsch R, Towne JB. Identification of *Staphylococcus epidermidis* vascular graft infections: a comparison of culture techniques. *J Vasc Surg.* 1989 May;9(5):665-70.
7. Bandyk DF, Novotney ML, Back MR, Johnson BL, Schmacht DC. Expanded application of in situ replacement for prosthetic graft infection. *J Vasc Surg.* 2001 Sep;34(3):411-19; discussion 419-20.
8. Clagett GP, Bowers BL, Lopez-Viego MA, Rossi MB, Valentine RJ, Myers SI, et al. Creation of a neo-aortoiliac system from lower extremity deep and superficial veins. *Ann Surg.* 1993 Sep;218(3):239-48; discussion 248-49.

9. Kieffer E, Gomes D, Chiche L, Fléron MH, Koskas F, Bahnini A. Allograft replacement for infrarenal aortic graft infection: early and late results in 179 patients. *J Vasc Surg.* 2004 May;39(5):1009-17.
10. Bisdas T, Brecht M, Pichlmaier M, Aper T, Wilhelm M, Bisdas S, et al. Eight-year experience with cryopreserved arterial homografts for the in situ reconstruction of abdominal aortic infections. *J Vasc Surg.*

Адрес для корреспонденции

88000, Украина,
г. Ужгород, ул. Университетская, д. 10,
ВГУЗ «Ужгородский национальный университет»,
тел. моб.: +380 50 558 82 11,
e-mail: i.koplovets@gmail.com,
Кополовец Иван Иванович

Сведения об авторах

Sihotský V., PhD, заместитель заведующего клиникой сосудистой хирургии по педагогической работе, сосудистый хирург, Восточный Словацкий институт сердечно-сосудистых заболеваний «VÚSCH», университет П.Й. Шафарика, медицинский факультет, г. Кошице, Словакия.

Berek P., PhD, заведующий отделением сосудистой хирургии, Восточный Словацкий институт сердечно-сосудистых заболеваний «VÚSCH», университет П.Й. Шафарика, медицинский факультет, г. Кошице, Словакия.

Koplovets I., PhD, научный сотрудник ВГУЗ «Ужгородский национальный университет», г. Ужгород, Украина, сосудистый хирург, Восточный Словацкий институт сердечно-сосудистых заболеваний «VÚSCH».

Kubiková M., PhD, сосудистый хирург, Восточный Словацкий институт сердечно-сосудистых заболеваний «VÚSCH», университет П.Й. Шафарика, медицинский факультет, г. Кошице, Словакия.

Tomečko M., PhD, сосудистый хирург, Восточный Словацкий институт сердечно-сосудистых заболеваний «VÚSCH», университет П.Й. Шафарика, медицинский факультет, г. Кошице, Словакия.

Stančúková M., PhD, хирург, хирургическая клиника №1, университет П.Й. Шафарика, медицинский факультет, г. Кошице, Словакия.

Drahovský I., PhD, заведующая клиникой радиодиагностики №1, университет П.Й. Шафарика, медицинский факультет, г. Кошице, Словакия.

Frankovičová M., PhD, профессор, заведующая клиникой сосудистой хирургии, Восточный Словацкий институт сердечно-сосудистых заболеваний «VÚSCH», университет П.Й. Шафарика, медицинский факультет, г. Кошице, Словакия.

Информация о статье

Поступила 13 марта 2017 г.
Принята в печать 26 июня 2017 г.
Доступна на сайте 6 ноября 2017 г.

- 2010 Aug;52(2):323-30. doi: 10.1016/j.jvs.2010.02.277.
11. Oderich GS, Bower TC, Hofer J, Kalra M, Duncan AA, Wilson JW, et al. In situ rifampin-soaked grafts with omental coverage and antibiotic suppression are durable with low reinfection rates in patients with aortic graft enteric erosion or fistula. *J Vasc Surg.* 2011 Jan;53(1):99-106, 107.e1-7; discussion 106-7. doi: 10.1016/j.jvs.2010.08.018.

Address for correspondence

88000, Ukraine, Uzhhorod,
Universitetskaya st., 10,
Uzhhorod National University
Tel.: +380 50 558 82 11
E-mail: i.koplovets@gmail.com
Ivan I. Koplovets

Information about the authors

Sihotský V., PhD, Vascular Surgeon, Clinic of Vascular Surgery, East Slovakian Cardiovascular Institute and P.J. Šafárik's University, Košice, Slovakia. Deputy of the Head of the Department for Pedagogics.

Berek P., PhD, Vascular Surgeon, Deputy of the Head of the Department for Treatment Clinic of Vascular Surgery, East Slovakian Cardiovascular Institute and P.J. Šafárik's University, Košice, Slovakia.

Koplovets I., PhD, Researcher of DSME «Uzhhorod National University», Uzhhorod, Ukraine. Vascular surgeon, Clinic of Vascular Surgery, East Slovakian Cardiovascular Institute, Košice, Slovakia.

Kubiková M., PhD, vascular surgeon, Clinic of Vascular Surgery, East Slovakian Cardiovascular Institute and P.J. Šafárik's University, Košice, Slovakia.

Tomečko M., PhD, Vascular Surgeon, Clinic of Vascular Surgery, East Slovakian Cardiovascular Institute and P.J. Šafárik's University, Košice, Slovakia.

Stančúková M., General Surgeon, I. Surgical Clinic, University Hospital of J. Pasteur and P.J. Šafárik's University, Košice, Slovakia.

Drahovský I., PhD, Head of the Department, I. Clinic of Radiodiagnosics and Image Techniques, University Hospital of J. Pasteur and P.J. Šafárik's University, Košice, Slovakia.

Frankovičová M., PhD, Professor, Head of the Department, Clinic of Vascular Surgery, East Slovakian Cardiovascular Institute and P.J. Šafárik's University, Košice, Slovakia.

Article history

Arrived 13 March 2017
Accepted for publication 26 June 2017
Available online 6 November 2017